

New Hope

for Kids with Cerebral Palsy and Brain Injuries

By Richard Neubauer, M.D.,
& Maureen Hall-Dickenson, B.Sc.
with Virginia I. Neubauer

HYPERBARIC OXYGEN THERAPY IS PROVING TO BE ABLE TO TAKE CHILDREN SIGNIFICANTLY BEYOND THE LIMITS OF THE IMPROVEMENTS THAT WERE PREVIOUSLY THOUGHT POSSIBLE.



HYPERBARIC oxygen Therapy (HBOT) is a medical treatment that helps the body heal itself by making oxygen available to tissues that, through illness or trauma, are not receiving an adequate supply. We all know that oxygen is necessary for life, but its role is complex, and within the body it performs a multitude of functions. Therapeutically, **HYPERBARIC** oxygenation has a positive effect on the central nervous system; it reduces swelling, repairs the blood-brain barrier, and stabilizes cell membranes. It increases the ability of white blood cells to clean up damaged areas and, over the long-term, it creates a whole new supply of blood vessels called angiogenesis. Also, it provides a mechanism whereby, if there is damaged tissue in the brain due to an inadequate supply of blood, and thus also oxygen (hypoxic ischemia), **HYPERBARIC** therapy may be used immediately to deliver the necessary oxygen to the tissue for viability, damage control and healing.

Hyperbaric oxygenation has been used for approximately 100 years. It was originally employed by the diving industry for the treatment of "the bends." Since the late 1950s its use has been expanded to include many medical conditions, including wound healing, radiation damage, bone infections, the surgical restoration of severed limbs, intestinal pathologies, such as Crohn's disease, as well as various types of brain damage.

In HBOT, a patient lies in a sealed chamber filled with 100 percent oxygen, and the interior pressure is increased, usually up to 1-1/2 atmospheres. ("Hyper" means increased and "baric" means atmosphere, thus the name of the chamber and therapy.) The patient does not receive increased oxygenation by the oxygen being "forced" into the body because of the pressure. Rather, following basic laws of physics, oxygen under pressure is dissolved into the

patient's body fluids, such as lymph, blood plasma, urine, and most importantly, the cerebral spinal fluid (the fluid that covers the entire central nervous system, and that surrounds and nourishes the brain). With HBOT, the amount of oxygen the body fluids contain can increase up to twenty-fold.

Normally in the body, oxygen is delivered to the tissue spaces by way of the hemoglobin in the blood. When oxygen is transported by the blood cells, the body's cells have to work for that oxygen; it takes energy for the red blood corpuscles to release the oxygen into tissue cells and to receive carbon dioxide to be exhaled through the lungs. With **HYPERBARIC** oxygen delivery, it requires no work to oxygen-enrich the cells directly, because all of the fluids and tissues are saturated with the oxygen. This greatly increases the availability of oxygen that is immediately available for the cells to use.

HBOT has been employed as a treatment for a variety of neurological indications, including emergency situations such as drowning, smoke inhalation, and electrocution, and chronic conditions of decreased blood flow and oxygen deficiency to the brain, traumatic brain injury, and multiple sclerosis. As early as 1964 studies published in the medical journal the Lancet demonstrated the positive effects of **HYPERBARIC** oxygenation on oxygen-deprived "blue babies." Thus, using HBOT to treat brain-injured children is not new, and it has been more recently acclaimed for its beneficial use in children with cerebral palsy (CP).

Cerebral palsy is not a specific illness; it is a catch-all term referring to any neurological disability in children under fourteen years of age (please see the sidebar, "Causes of Cerebral Palsy"). Traumatic brain injuries at times fall into this classification, and illnesses from multiple causes. Conditions resulting in decreased neurological blood flow and oxygenation can stem from an event that occurs in the womb (including placental separation, or obstruction [embolus] of the amniotic fluid); at the time of birth (including maternal trauma, cerebral hemorrhage, or suffocation with the umbilical cord around the neck); and for newborns (possible trauma, shaken baby syndrome, infections, and intestinal dysfunction.)



Dr. Paul Yutsis, Director of the Yutsis Center for Integrated Medicine in Brooklyn, New York, talks with one of his patients during a **HYPERBARIC** oxygen therapy session.

Cerebral palsy can be mild, with its only symptoms being minor developmental delays, to very serious, with severe mental retardation and marked spasticity (severe muscle contraction) or even complete limpness with the inability to develop motor skills like holding the head up or rolling over and/or the need for feeding tubes because of the inability to swallow.

Other prenatal causes can be microbial in origin, such as German measles, syphilis, herpes, hepatitis, meningitis, and infections due to parasites, bacteria, or viruses. In all instances, there is an insult to the brain. The severity of the illness is contingent upon the location of the area of the brain affected. According to several studies, the spastic form of CP is the most prevalent (more than 80% of the cases) of the clinical symptoms. Spastic muscles are in permanent contraction, marked by uncontrollable intermittent muscle contraction and relaxation (clonus.)

A Tragic Medical Mistake for 45 Years!

It is unfortunate that nearly all newborns today are deprived of appropriate oxygen therapy because of the fear it will cause the formation of fibrous tissue in the eye (retrolental fibroplasia) causing blindness. This is due to the effects of the introduction of oxygen tents and incubators following World War II. Premature infants were given supplementary oxygen to improve their chances of survival, and levels up to 70 percent were given for extended periods. Epidemics of blindness followed in the 1950s, which led to a restriction of the level of supplemental oxygen to 40 percent. A reduction in the incidence of blindness followed, which confirmed the involvement of oxygen in the eye disease (retinopathy).

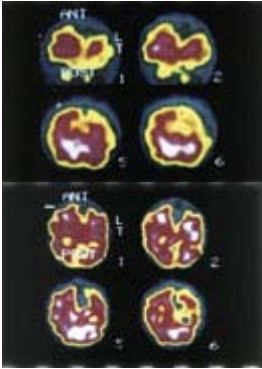
Since that time, every medical student has been taught that the retinopathy of the premature (ROP) is caused by oxygen toxicity. With the use of oxygen restricted, by 1964, Dr. A. D. McDonald had recorded a significant rise in the incidence of cerebral palsy compared with levels before then. However, research brought to light only within the last few months by P. B. James, M.D., of Scotland, has demonstrated that it was the withdrawal from the oxygen environment that caused retinal problems. Resubmersion, time and time again, completely rectified the problem. Thousands of cases of CP developed needlessly because of this fear of oxygen toxicity.

HYPERBARIC oxygenation does not cause retrolental fibroplasia and now offers a new modality whereby the reduction in spasticity may be significantly decreased. We must immediately institute this practice to rectify what has been a tragic medical mistake.

SPECT IMAGING

New techniques with ultra sound, magnetic resonance imaging (MRI) and SPECT ("Single Photon Emission Computerized Tomography") scanning, can detect problems early and appropriate treatments should be instituted as soon as the diagnosis is made. SPECT is a metabolic type of functional imaging that actually shows what the brain is doing at a point and time. Using SPECT scanning one can see what effect any therapeutic process produces. This procedure uses a gamma camera that is often used by cardiologists for heart checking. An infinitesimal amount of radioactive material is injected into the patient. This circulates through the body, crosses the blood-brain barrier, and localizes in the brain. The patient then lies still while a camera picks up the signals and, through a computer, plots out a picture of the blood flow and the metabolism of the brain.

HYPERBARIC oxygenation is administered in a cylinder chamber like the ones used for the treatment of divers. There are two types of chambers. There are small chambers ("monoplace") for one patient in which the chamber is compressed with 100 percent oxygen. The other type is a multi-place chamber. Actually, in China, we have seen models that hold up to 36 patients, and under these circumstances, the chamber is compressed with air with the oxygen administered either with a hood or a mask.



SPECT IMAGING

SPECT scan images of the two case histories discussed beginning on the next page. On the top is GB, a 7-year-old male, with pre-treatment images to the left, and images on the right taken after 86 HBOT treatments. Below is EW, a 3-year old, showing pre-treatment on the left and after 31 HBOT treatments on the right. The yellow areas indicate non-functioning areas of the brain due to lack of oxygen. The post-treatment scans show significantly increased blood perfusion (red areas). There is an 80% to 90% correlation between brain blood perfusion and improved motor and cognitive skills in patients.

HYPERBARIC oxygen therapy is an extremely safe and non-invasive procedure. The patient is placed in a **HYPERBARIC** chamber (in many cases the parent can go into the chamber with a small child) and the pressure is appropriately increased as they breathe pure oxygen. There is little to no sensation, except for the pressure increase at the beginning and decrease at the end of the treatment. These changes may be noted as similar to the ascent and descent in an airplane. In fact, the most common side effect to HBOT (less than 5 percent of patients) is simply some minor pain or squeeze in the ears or sinuses when these pressure changes take place.

In nearly all cases of cerebral palsy in children there are areas of the brain that are low in oxygen. These areas are functioning below normal, if at all, and may be seen clearly on a SPECT scan. The SPECT scan is different from MRI, in that SPECT scanning shows function and not detailed anatomy.

With the use of oxygen under pressure a major advantage takes place. This increases the saturation of the hemoglobin that normally carries oxygen relatively slightly—from possibly 96 percent up to 100 percent. But HBOT increases the plasma, that is, the solution that holds the red cells containing hemoglobin, by up to 2,000 percent.

In a 1998 pilot study, HBOT improved the function in children with paralysis of the legs (spastic diplegia). However, because of the limits of the study (small sample size, no control group, minimal number of treatments), these results must be interpreted with caution and further research is needed to ascertain the true potential of this treatment and its long term effects for children with CP. A double-blind randomized study has begun. Further studies with encouraging data are now being performed at Cornell University and New York University.

A study recently completed at the McGill University, Montreal, Canada, was highly positive, with significant improvement in increased motor skills, including sitting, walking and manual dexterity, and decreased spasticity. The results were so encouraging that the government has authorized a grant of nearly 2 million dollars for further studies. A double blind study on the use of HBOT and brain injury was recently completed at the University of Texas in Galveston with equally positive results. Furthermore, it is noted that in the United Kingdom that there are now three hundred children undergoing treatment and the results are equal to those of the study at McGill. The evidence now has become compelling with reports from around the world, including Mexico and Brazil. From the standpoint of safety, there are 110 **HYPERBARIC** centers in the UK that have treated patients with over 1.25 million hours without incident. At the Ocean **HYPERBARIC** Center, we have treated over 80 patients with CP and brain injuries (ages range from three weeks to fourteen years). A large percentage have shown clinical improvement documented by SPECT imaging.

CASE HISTORIES

The first case, GB, involves a 7-year-old male diagnosed with CP. The patient was a full term delivery. His parents were told that he was normal at the birth, but six to eight hours later, he was rushed into intensive care unit with respiratory distress. This patient came to the Ocean **HYPERBARIC** Center in a wheel chair along with his father. His cognitive level was a little below average; he had no control of his balance; and there was marked spasticity of the left side. After 86 HBOT treatments, he was able to stand by himself for long periods of time and his balance had improved. His cognitive levels improved and he is more aware of his surroundings. There was significant decrease in spasticity and the patient is able take steps with a walker. When this patient returned home, these improvements had remained.

The second case, EW, is a 3-year-old patient who suffered from severe brain damage and low platelet count. He had difficulty breathing along with generalized sepsis (infected with pus-producing organisms). It is remarkable that this patient survived with his multiple illnesses. The patient received a total of 31 HBOT treatments. He is now able to sit up and hold a cup on his own for the first time. He made three more sounds, pointing, and is much more alert. The patient is aware of his surrounding and grabs at everything.

HYPERBARIC oxygen seems to be the most logical approach to the correction of the decreased blood flow/oxygenation that is responsible for cerebral palsy and also similar situations with the brain injured children. Unfortunately, this is not taught by all the medical school curricula and many doctors are unfamiliar with it; certainly if the doctor is not familiar with it, he or she is not apt to prescribe it. Nevertheless, it is felt that the earlier this is done, the better. It does not only jump-starts the brain but it also creates a better environment for which neonates and young children to grow brain tissue. Long-term studies must be indicated-it will probably be ten to fifteen years before we really know the ultimate effect of **HYPERBARIC** oxygenation